PLACENTA PREVIA AFTER HYSTEROSCOPIC METROPLASTY IN A T-SHAPE UTERUS: A CASE REPORT.

Fernandez Sanahuja L[1], Baucells Nuri M[1], Urpí Tosar B[1], Bergueiro Flor A[1], Rueda García C[1], López-Yarto Elejabeitia M[1].

[1]*Obstetrics and Gynecology Department, Hospital del Mar, Parc de Salut Mar, Barcelona, Spain.*

AIM

T-shape uterus is a rare uterine malformation (0.2-10%), with narrow endometrial cavity due to thickened lateral walls, leading to a uterine cavity shape resembling letter T. Described etiologies vary from congenital malformation to uterine pathologies as adenomyosis and intrauterine synechiae. T-shape uterus may be associated with poorer reproductive and obstetrical outcomes such as higher prevalence of recurrent miscarriage, ectopic pregnancy and preterm delivery[1]. Hysteroscopic metroplasty with laser is a minimally invasive procedure that has been considered as a treatment option. Pregnancy outcomes after metroplasty seem to equiparate to general population results[2]. No association between this surgery and anomal placentation has been found in literature.

METHODS

A 43 year-old woman, with a history of Pelvic Inflammatory Disease (PID) grade III treated with endovenous antibiotic and further bilateral salpingectomy for symptomatic hydrosalpingx, and two previous miscarriages, consulted in an assisted reproduction clinic to start an IVF cycle. A routine 3D ultrasound was performed, where a uterine malformation was suspected. An office hysteroscopy brought additional information, with the final diagnosis of a T-shape uterus.

Due to her reproductive history, a surgical treatment was proposed. An operative hysteroscopy was performed with patient under general anesthesia. As seen in the images, the laser metroplasty released the adhesions on both lateral walls, obtaining an optimal endometrial cavity and a correct visualization of both tubal ostia. A 3D ultrasound confirmed a normalized uterine cavity.

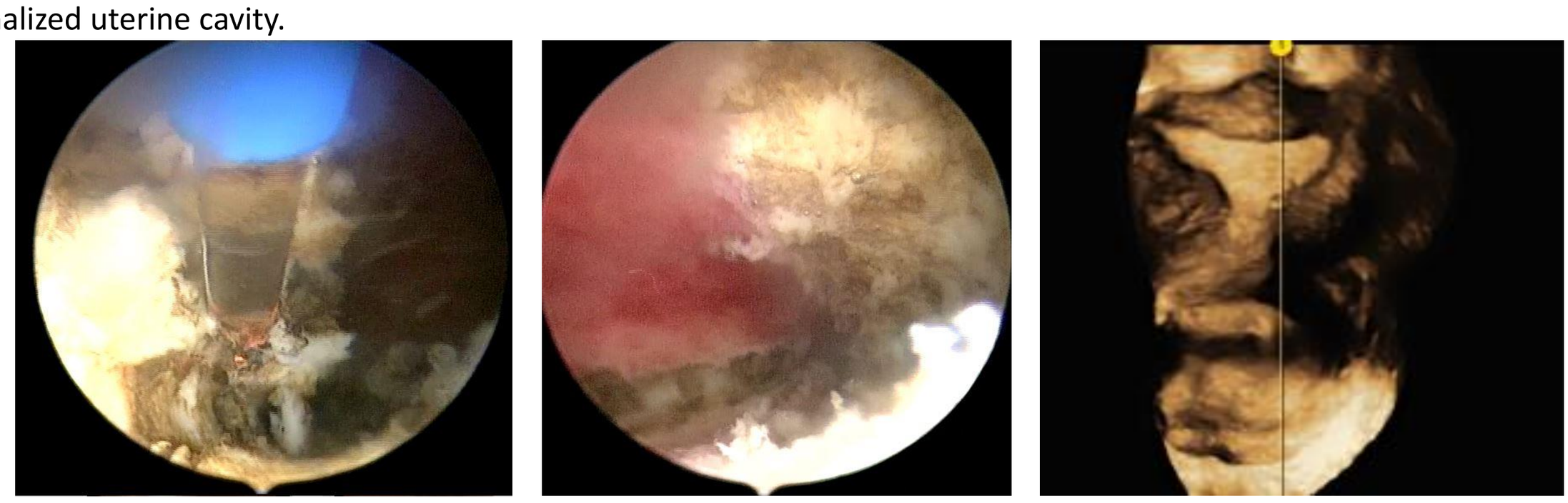

RESULTS

3-months after surgery, the patient started an IVF-ovodonation cycle achieving pregnancy on her first attempt. On the second trimester ultrasound she was diagnosed of a total occlusive placenta previa with no signs of acretism.

A healthy 38 weeks-baby was born trough an elective cesarean section. No other placental anomalies or adverse obstetrical outcomes were noted.

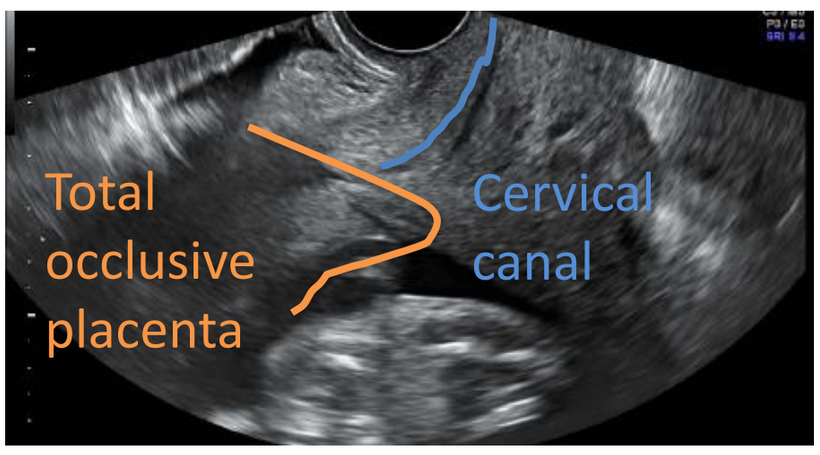

CONCLUSIONS

T-shape uterus etiology remains uncertain, although intrauterine synechiae have been proposed as a possible cause. Hysteroscopic metroplasty is a minimally invasive and safe procedure which potentially enhances reproductive outcomes for patients with a history of reproductive impairment. In the presented patient's case, pregnancy was accomplished after surgical restoration of the uterine cavity shape, but placentation occurred anomaly. Both T-shape uterine metroplasty and placenta previa are infrequent in general population, so special attention was driven to explore possible causality. Nevertheless, no literature describing this potential association was found by the authors.

The authors declare no conflicts of interest. None received grant support for this study neither for clinical activity from any industry related to the present congress.

1. Coelho Neto MA, Ludwin A, Petraglia F, Martins WP. Definitions, prevalence, clinical implications and treatment of T-shaped uterus: systematic review. Ultrasound Obstet Gynecol. 2020;(August 2020):366-77. DOI: 10.1002/uog.23108
2. Garzon S, Laganà AS, Di Spiezio Sardo A, Alonso Pacheco L, Haimovich S, Carugno J, Vitale SG, Casarin J, Raffaelli R, Andrisani A, Zizolfi B, Cromi A, Ghezzi F, Franchi M, Vitagliano A. Hysteroscopic Metroplasty for T-Shaped Uterus: A Systematic Review and Meta-analysis of Reproductive Outcomes. Obstet Gynecol Surv. 2020 Jul;75(7):431-444. doi: 10.1097/OGX.0000000000000807. PMID: 32735685.