FRAGMENTATION OF INTRA-UTERINE CONTRACEPTIVE DEVICES

Fabregó Capdevila B; Castellà Cesari J; Agramunt García S; Fernandez Sanahuja L; Rubio Salazar R; Lopez-Yarto Elejabeitia M.

All authors have no conflicts of interest to declare

AIM

Intra-uterine contraceptive devices (IUD) are an effective and safe method for long-term reversible contraception with minimal tolerable side effects. Removal of the device, is easy when the string is visible but can be challenging when it is no longer visible and patients can be referred to hysteroscopy. Fragmentation of IUD during its vital period or during their extraction can occur. In these cases, a hysteroscopic diagnosis and extraction of the fragments is recommended.

In our institution, we conducted a survey and found that once per week, 2 diagnostic hysteroscopies are performed in the setting of retained IUDs (entire or fragmented); approximately 80 cases per year. Nevertheless, in an important percentage of cases, an empty uterine cavity is objectivated, probably due to spontaneous expulsion prior hysteroscopy.

METHODS

We report the case of a 38 years-old nulliparous woman (1 caesarean section), that was referred to our centre. The patient was a Multiload IUD user since 4 years.

After an accidental fall while riding her bicycle, the patient refers a spontaneous expulsion of the IUD string and a fragment of the central part of the T. After a pelvic X-ray (because of accidental fall) and a transvaginal ultrasound, the IUD is seen on the pelvis and the patient is referred for a hysteroscopy.

A Bettochi hysteroscope is introduced. The vaginoscopy reflects a stenosis of the external os. The cervix is then progressively dilated for a mechanical dilatation and a fragment of the central part of the IUD is seen and removed. Hysteroscope is introduced again and the presence of the right lateral IUD leg in cervical canal is objectivated. Left lateral leg is found inside the uterine cavity. All the IUD fragments are removed.

RESULTS

IUDs are a widely used method of contraception worldwide. Complications seen with an intrauterine device are relatively uncommon but include IUD lost or fragmentation and therefore, hysteroscopy should be considered. In our institution, and increasing number of hysteroscopies in the setting of IUD complications are performed every week. Not only fragmentation of IUD is seen during extraction process but also during its vital period. We ask ourselves why we are performing everyday more hysteroscopies in this particular setting. Could it be an IUD-material problem?

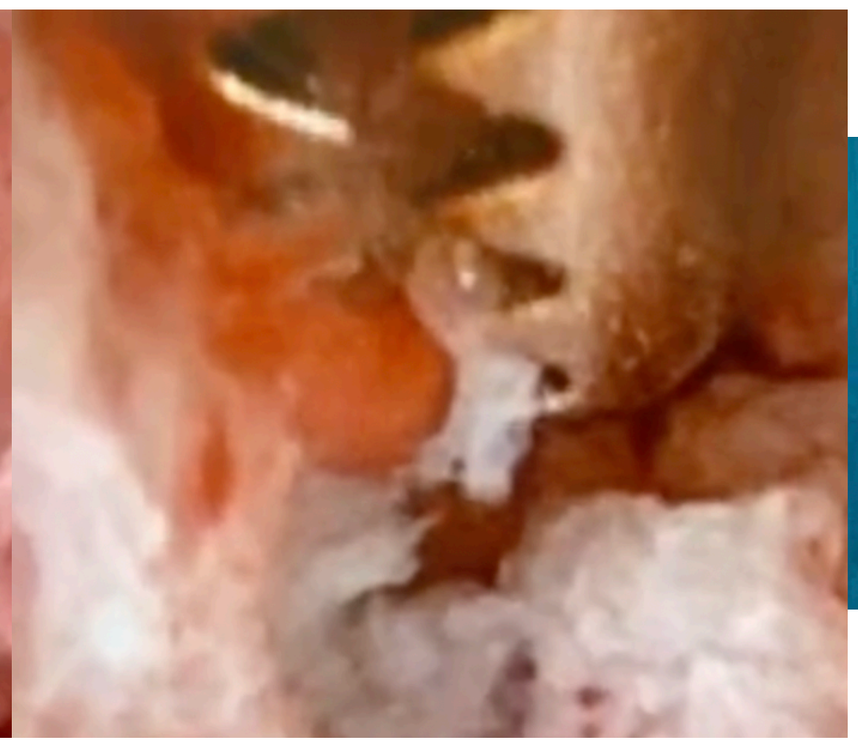

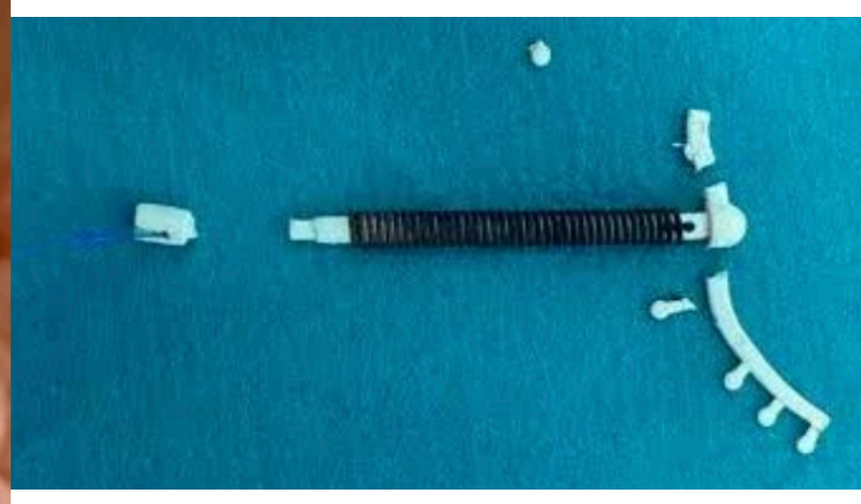

CONCLUSIONS

IUDs are one of the most effective forms of contraception available today. However, hysteroscopy has now and increasing use in the setting of IUD retention/removal, sometimes because of IUD fragmentation. Removing of all IUD fragments can be challenging.

Parc de Salut Barcelona MAR